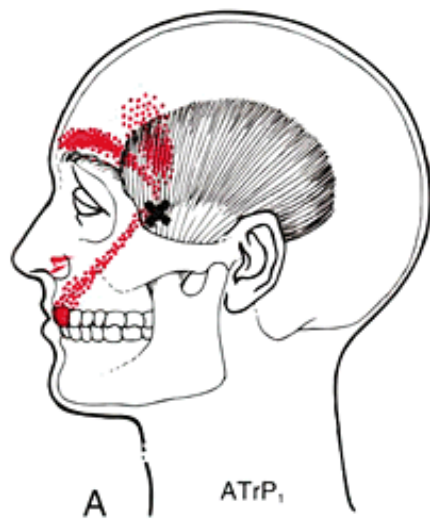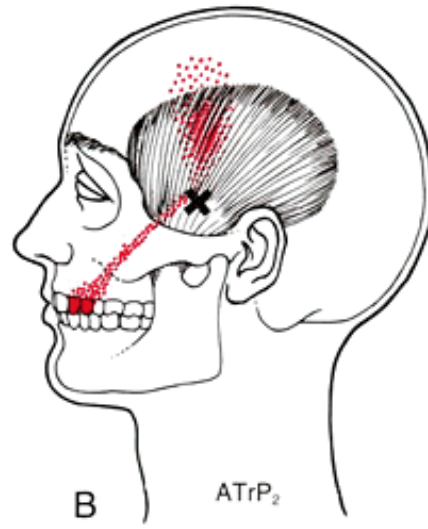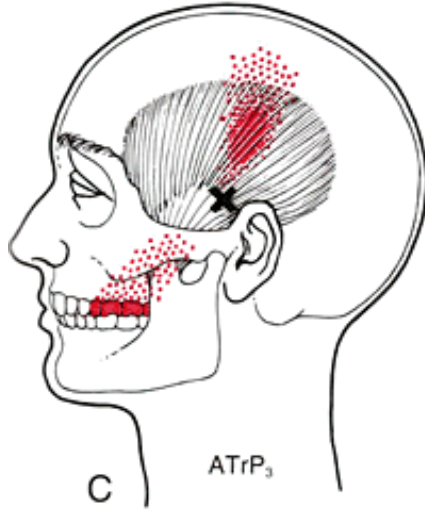




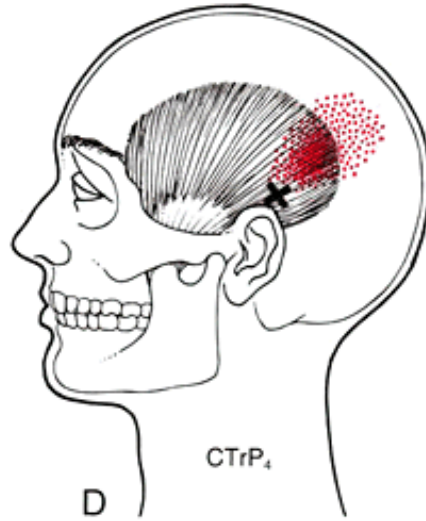
A ATrP₁



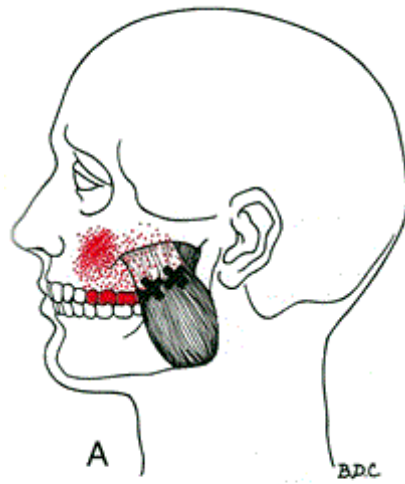
B ATrP₂



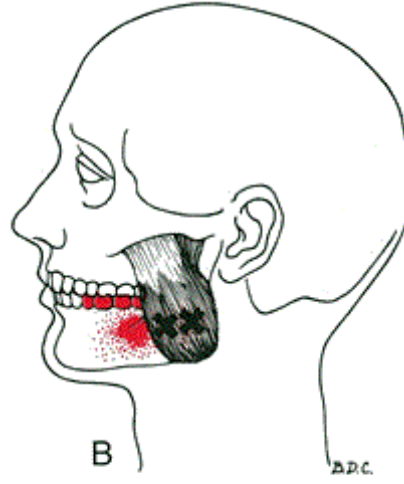C ATrP₃



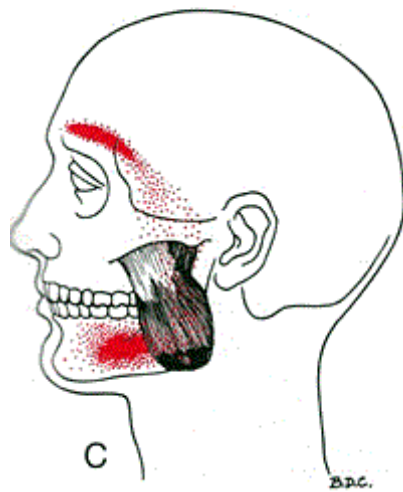D CTrP₄



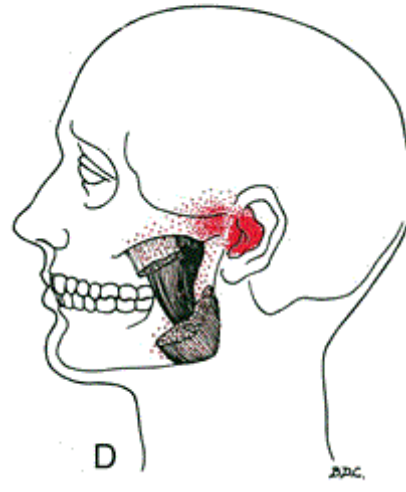
A BDC



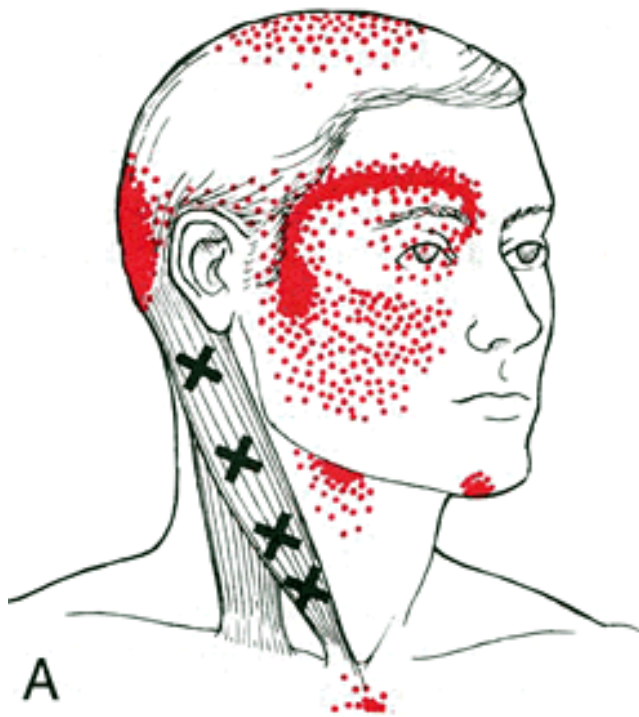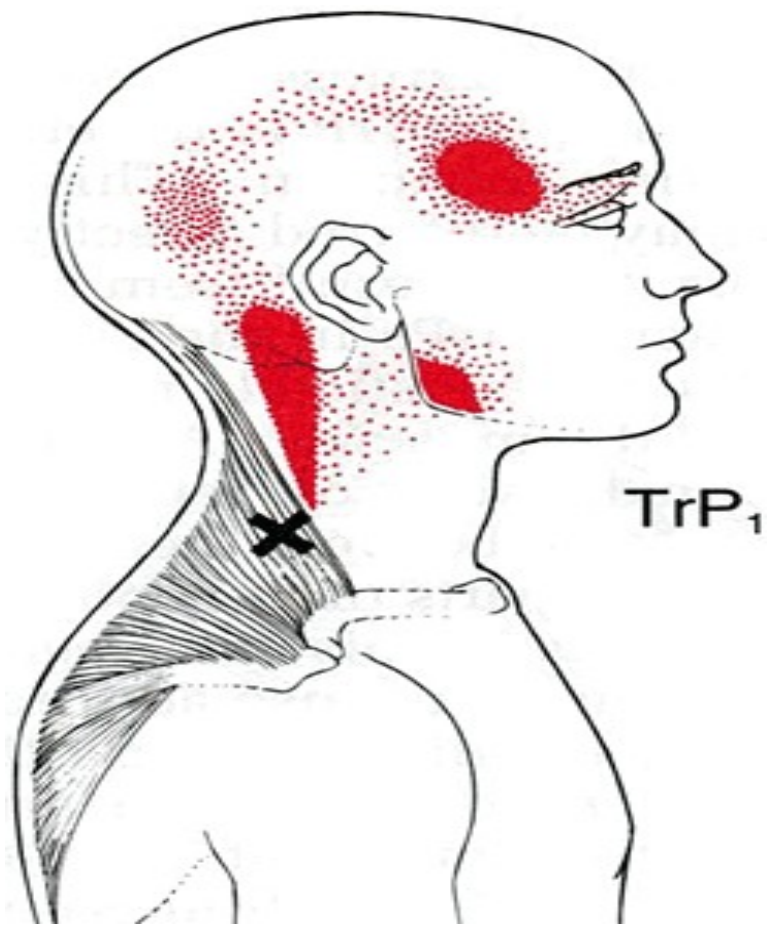
B BDC



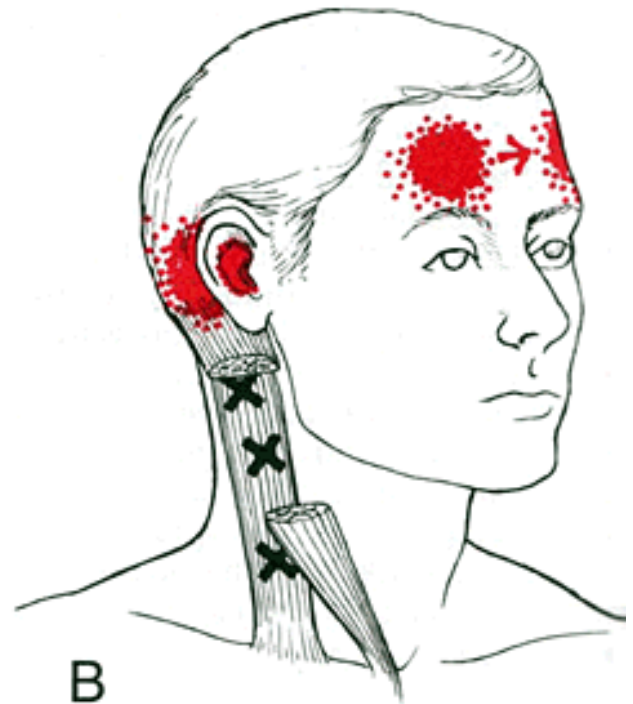C BDC



D BDC



Sternal division



Clavicular division